

# Bisphosphonate-Induced Exposed Bone (Osteonecrosis/Osteopetrosis) of the Jaws: Risk Factors, Recognition, Prevention, and Treatment

Robert E. Marx, DDS,\* Yob Sawatari, DDS,†  
Michel Fortin, DMD, PhD,‡ and  
Vishtasb Broumand, DMD, MD§

**Purpose:** Bisphosphonates inhibit bone resorption and thus bone renewal by suppressing the recruitment and activity of osteoclasts thus shortening their life span. Recently three bisphosphonates, Pamidronate (Aredia; Novartis Pharmaceuticals, East Haven, NJ), Zoledronate (Zometa; Novartis Pharmaceuticals), and Alendronate (Fosamax; Merck Co, West Point, VA) have been linked to painful refractory bone exposures in the jaws.

**Materials and Methods:** One hundred-nineteen total cases of bisphosphonate-related bone exposure were reviewed.

**Results:** Thirty-two of 119 patients (26%) received Aredia, 48 (40.3%) received Zometa, 36 (30.2%) received Aredia later changed to Zometa, and 3 (2.5%) received Fosamax. The mean induction time for clinical bone exposure and symptoms was 14.3 months for those who received Aredia, 12.1 months for those who received both, 9.4 months for those who received Zometa, and 3 years for those who received Fosamax. Sixty-two (52.1%) were treated for multiple myeloma, 50 (42%) for metastatic breast cancer, 4 (3.4%) for metastatic prostate cancer and 3 (2.5%) for osteoporosis. Presenting findings in addition to exposed bone were 37 (31.1%) asymptomatic, 82 (68.9%) with pain, 28 (23.5%) mobile teeth, and 21 (17.6%) with nonhealing fistulas. Eighty-one (68.1%) bone exposures occurred in the mandible alone, 33 (27.7%) in the maxilla, and 5 (4.2%) occurred in both jaws. Medical comorbidities included the malignancy itself 97.5%, previous and/or maintenance chemotherapy 97.5%, Dexamethasone 59.7%. Dental comorbidities included the presence of periodontitis 84%, dental caries 28.6%, abscessed teeth 13.4% root canal treatments 10.9%, and the presence of mandibular tori 9.2%. The precipitating event that produced the bone exposures were spontaneous 25.2%, tooth removals 37.8%, advanced periodontitis 28.6%, periodontal surgery 11.2%, dental implants 3.4% and root canal surgery 0.8%.

**Conclusions:** Complete prevention of this complication is not currently possible. However, pre-therapy dental care reduces this incidence, and non-surgical dental procedures can prevent new cases. For those who present with painful exposed bone, effective control to a pain free state without resolution of the exposed bone is 90.1% effective using a regimen of antibiotics along with 0.12% chlorohexidine antiseptic mouth.

© 2005 American Association of Oral and Maxillofacial Surgeons  
*J Oral Maxillofac Surg* 63:1567-1575, 2005

\*Professor of Surgery and Chief, University of Miami Miller School of Medicine, Division of Oral and Maxillofacial Surgery, Miami, FL.

†Private Practice, Oral Surgery, Miami, FL; Former Resident, University of Miami Miller School of Medicine, Division of Oral and Maxillofacial Surgery, Miami, FL.

‡Oral and Maxillofacial Surgery Department, l'Enfant-Jésus Hospital Faculty of Dentistry, Laval University, Quebec City, Quebec, Canada; Former Fellow in Tumor and Reconstructive Surgery, University of Miami Miller School of Medicine, Division of Oral and Maxillofacial Surgery, Miami, FL.

§Fellow in Tumor and Reconstructive Surgery, University of Miami School of Medicine, Division of Oral and Maxillofacial Surgery, Miami, FL.

Address correspondence and reprint requests to Dr Marx: Miller School of Medicine, Division of Oral and Maxillofacial Surgery, University of Miami, 9380 SW 150th St, Suite 190, Miami, FL 33157; e-mail: rmarx@med.miami.edu

© 2005 American Association of Oral and Maxillofacial Surgeons  
0278-2391/05/6311-0002\$30.00/0

doi:10.1016/j.joms.2005.07.010

Painful exposure of bone in the mandible and maxilla of patients receiving the bisphosphonates pamidronate (Aredia; Novartis Pharmaceuticals, East Hanover, NJ) and zoledronate (Zometa; Novartis Pharmaceuticals) was first reported by Marx in 2003.<sup>1</sup> Since then, several authors have reported additional cases,<sup>2-5</sup> and many dental professionals, particularly oral and maxillofacial surgeons, have identified numerous unpublished cases. The original publication by Marx<sup>1</sup> reported 36 diagnosed cases under treatment, which has increased to 76 cases as of this writing. Among the other publications, Migliorati<sup>2</sup> reported 5 cases, Ruggerio et al<sup>3</sup> reported 63 cases, Carter and Gross<sup>4</sup> reported 4 cases, and Estilo et al<sup>5</sup> reported 13 cases. The authors have documented 43 additional cases reported to them by colleagues nationwide who have sought advice regarding prevention and management of this condition. The purpose of this article is to review the possible mechanisms of this complication, outline strategies to prevent it, review treatment options, and report treatment outcomes.

Today, bisphosphonates are commonly prescribed to stabilize bone loss caused by osteoporosis in millions of postmenopausal women. The strategy in the treatment of osteoporosis is to inhibit the resorption of trabecular bone by osteoclasts and hence preserve its density. For this purpose, oral bisphosphonates are prescribed and include etidronate (Didronel; Procter and Gamble, Cincinnati, OH) risedronate (Actonel; Procter and Gamble), tiludronate (Skelid; Sanofi-Synthe Lab Inc, New York, NY), and alendronate (Fosamax; Merck Co, West Point, PA). More potent bisphosphonates are delivered intravenously (IV) and are indicated to stabilize metastatic cancer (primarily breast and prostate) deposits in bone, and to treat the bone resorption defects of multiple myeloma and correct severe hypercalcemia. These are pamidronate and zoledronate. In addition to the drugs mentioned here, several other bisphosphonates are known that are either not commonly used in the United States or that remain experimental.<sup>6</sup>

The suggested term applied to this form of painful bone exposure so far has been *osteonecrosis of the jaws*, because it has thus far only been reported in the jaws. However, this form of osteonecrosis (dead bone) more closely resembles osteopetrosis, which has the endpoint of producing dead bone (osteonecrosis). Therefore, it should not be confused with other known causes of exposed bone in the jaws or with various forms of osteonecrosis found in long bones. The most common type of osteonecrosis of the jaws is osteoradionecrosis, which is well known to most dental and medical professionals.<sup>7,8</sup> This condition results when the high linear energy transfer from radiotherapy lyses the populations of stem cells,

endosteal osteoblasts, and vascular endothelial cells, producing an avascular bone necrosis. Less common but also well known is exposed bone from osteonecrosis of the jaws related to osteomyelitis, which results from thrombosis of the small blood vessels in bone in turn causing osteocyte and osteoblast death. This type of osteonecrosis is manifested either as an obvious exposed black necrotic bone, as is found in classic mucormycosis, or as a more subtle white alveolar ridge or lingual cortex exposure and drainage, as is found in bacterial osteomyelitis. Rarely found in the jaws is a steroid-induced form of osteonecrosis that is much more common in long bones, and, unlike the bisphosphonate-induced necrotic bone, it almost never produces exposed bone.<sup>9</sup> Additionally, rare cases of osteonecrosis have been reported in long bones and even in the jaws related to local invasive cancers, human immunodeficiency virus,<sup>10</sup> systemic lupus erythematosus,<sup>11</sup> and thrombophilia or hypofibrinolysis,<sup>12</sup> none of which is present in the bisphosphonate-induced cases.

## Materials and Methods

Seventy-six consecutive individuals referred to the University of Miami Division of Oral and Maxillofacial Surgery (Miami, FL) who presented with exposed bone associated with bisphosphonates and 43 cases well documented by colleagues were reviewed to determine the type, dosage, and duration of their bisphosphonate therapy, why it was indicated, presenting findings, comorbidities, and the event that incited the bone exposure. Of these 119 patients, 97 have been followed for 1 year or more and their response to treatment and outcomes recorded.

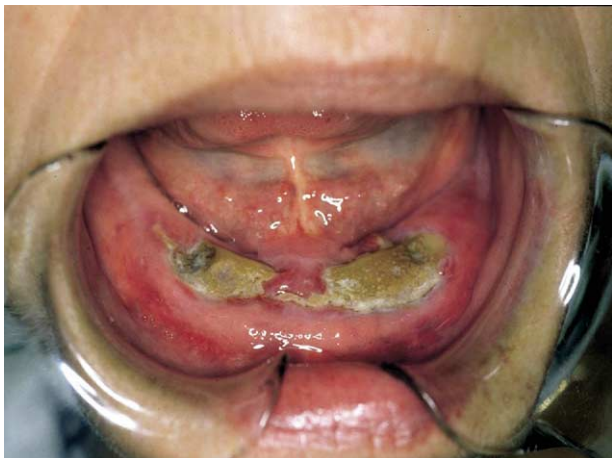## Results

### TYPE OF BISPHOSPHONATE DRUG PRESCRIBED

Of the 119 patients followed, 32 (26%) were receiving pamidronate, 48 (40.3%) were receiving zoledronate, 36 (30.2%) were receiving pamidronate initially and later were changed to zoledronate, and 3 (2.5%) were receiving alendronate. Thirty-three of these 119 patients (27.7%) also had a history of cigarette smoking.

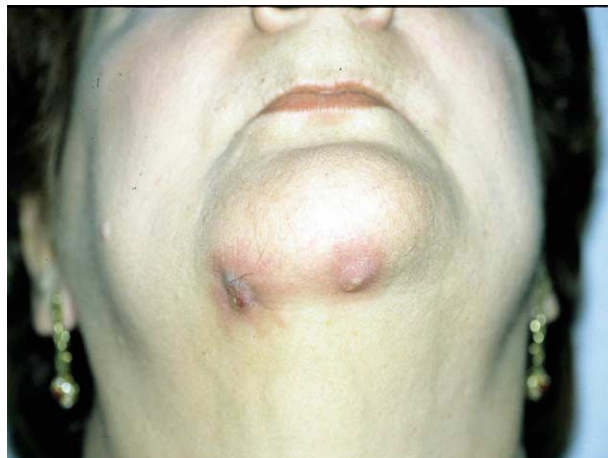### DOSAGE AND DURATION OF BISPHOSPHONATE THERAPY

The patients on pamidronate received 90 mg IV once every 3 weeks or 1 month, and those on zoledronate received 4 mg at the same intervals. Of the 3 patients receiving alendronate, 1 was taking 10 mg by mouth daily for 6 years and the other 2 were taking 10 mg by mouth daily for 3 and 2 years, respectively.



**FIGURE 1.** Exposed necrotic bone in the mandible related to pamidronate.

*Marx et al. Bisphosphonate-Induced Exposed Bone of Jaws. J Oral Maxillofac Surg 2005.*



**FIGURE 2.** Draining oral cutaneous fistulas representing secondary infections from an exposed mandible in the oral cavity from zoledronate.

*Marx et al. Bisphosphonate-Induced Exposed Bone of Jaws. J Oral Maxillofac Surg 2005.*

#### INDUCTION TIME FOR CLINICAL BONE EXPOSURE

The mean duration from first use of the drug to the first recognition of exposed bone, either by the patient or by a dental/medical practitioner, was 14.3 months for those taking pamidronate alone, 12.1 months for those who were switched from pamidronate to zoledronate, and 9.4 months for those who used zoledronate alone. In the 3 cases of bone exposure associated with alendronate, the mean duration was 3 years.

#### INDICATIONS FOR BISPHOSPHONATE THERAPY

Sixty-two of the 119 patients (52.1%) were treated with bisphosphonates for multiple myeloma, 50 (42%) for bone metastasis from breast cancer, 4 (3.4%) for bone metastasis from prostate cancer, and 3 (2.5%) for osteoporosis. Although multiple myeloma is more rare than either of these other conditions, it is associated with the greater number of cases because of its very presence in bone from its initial onset and therefore its more frequent indication for IV bisphosphonates therapy.

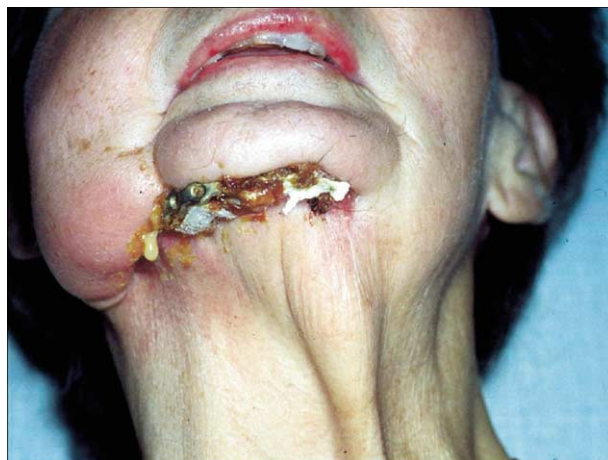#### PRESENTING FINDINGS

Thirty-seven patients (31.1%) presented with asymptomatic exposed bone discovered during a routine dental examination or by the patient through self examination. Eighty-two patients (68.9%) presented with an area of exposed bone and pain (Fig 1). Twenty-eight patients (23.5%) presented with 1 or more mobile teeth, and 21 (17.6%) with either a cutaneous fistula, a mucosal fistula, or bone exposed through the skin (Figs 2, 3). Eighty-seven patients (73.1%) presented with a positive radiographic finding: 85 with osteolysis, combined with osteosclerosis

(Fig 4), and 2 with osteosclerosis alone. Among the dental radiographic findings was a strong association with a widened periodontal membrane space, particularly at the furcation of the molar teeth (Fig 5).

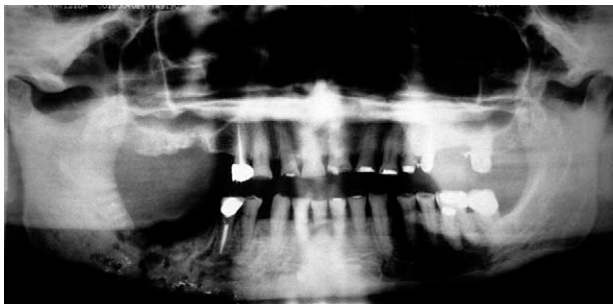#### LOCATION

The mandible and maxilla were the only bones involved in these exposures. Eighty-one exposures (68.1%) occurred exclusively in the mandible, 33 (27.7%) exclusively in the maxilla, and 5 (4.2%) simultaneously in the mandible and maxilla. The posterior mandible in the area of the molars was the most common site of exposure ( $n = 78$ ; 65.5%), followed by the posterior maxilla ( $n = 27$ ; 22.7%).



**FIGURE 3.** Significant cutaneous tissue loss with protruding bone and titanium plate with secondary infection as a result of attempted surgery to debride bisphosphonate-related osteonecrosis of the jaws.

*Marx et al. Bisphosphonate-Induced Exposed Bone of Jaws. J Oral Maxillofac Surg 2005.*



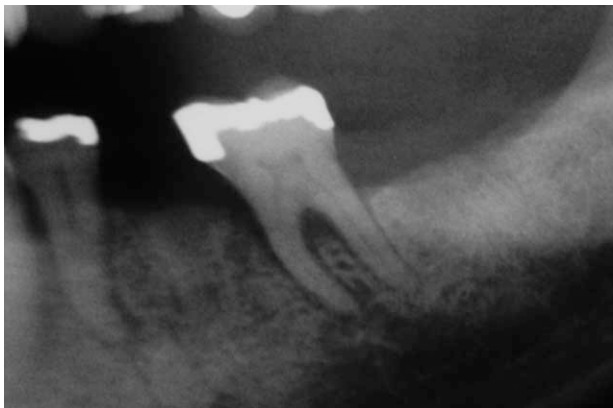
**FIGURE 4.** Osteolysis of the mandible with a pathologic fracture resultant from a tooth removal while the patient received pamidronate bisphosphonate therapy.

*Marx et al. Bisphosphonate-Induced Exposed Bone of Jaws. J Oral Maxillofac Surg 2005.*

## Comorbidities

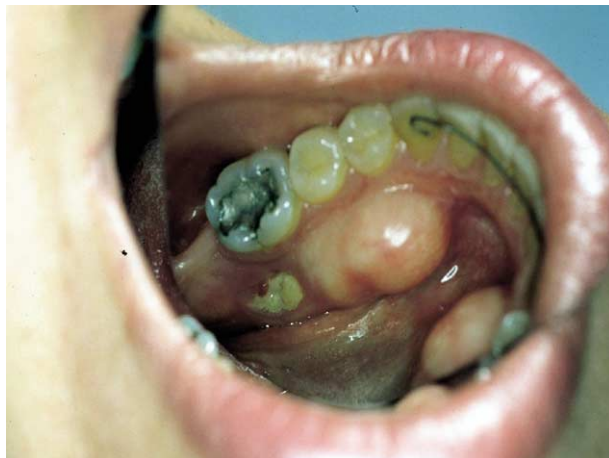### MEDICAL COMORBIDITIES

This group had a large variety and number of significant comorbidities, some of which cannot be quantified. The patient's underlying malignant disease—with its negative systemic effects on nutrition, the immune system, and day-to-day tissue homeostasis, not to mention the numerous deleterious cytokines known to be secreted by the tumors—must be considered the most significant comorbidity. However, it is important to note that 3 patients (2.5%) developed bisphosphonate-related exposed bone unrelated to cancer and that individuals with these same cancers and chemotherapy protocols but who had not received bisphosphonates did not develop this type of exposed bone. The most common morbidity was a history of systemic chemotherapy, which, as one would expect, was part of the standard treatment approach in 97.5% of these patients. However, a variety of drug protocols were followed, and concomi-



**FIGURE 5.** Bone loss between the roots of molar teeth (furcation involvement) is often an early sign of osteonecrosis of the jaws.

*Marx et al. Bisphosphonate-Induced Exposed Bone of Jaws. J Oral Maxillofac Surg 2005.*



**FIGURE 6.** Mandibular tori represent an anatomic comorbidity. Seen here is exposed bone related to zoledronate therapy over a multi-lobulated mandibular torus.

*Marx et al. Bisphosphonate-Induced Exposed Bone of Jaws. J Oral Maxillofac Surg 2005.*

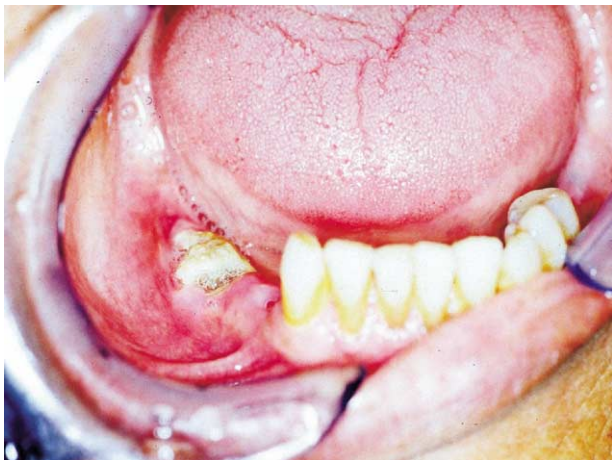tant bisphosphonate therapy, not any specific chemotherapy drug or protocol, was the only common denominator among all of these patients. The most common comorbidity drug was dexamethasone (Decadron; American Pharmaceutical Partners Inc, New York, NY), usually given in dosages ranging from 20 mg IV at the time of bisphosphonate injection to variable oral dosing throughout treatment. This was noted in 71 (59.7%) patients. After dexamethasone, various unquantifiable comorbidities, such as alcohol use, smoking, advanced age, and sometimes maintenance chemotherapy, were noted.

### DENTAL COMORBIDITIES

The most common dental comorbidity was clinically and radiographically apparent periodontitis. This bacterial plaque-related disease producing gingival inflammation and alveolar bone resorption was present in 100 (84%) of patients. Dental caries of teeth in the area of exposed bone was noted in 34 cases (28.6%), 16 (13.4%) of which had dental abscess formation. Thirteen teeth (10.9%) had previous root canal treatments with evidence of failure by virtue of an apical radiolucency or an inadequate fill. Of particular note, 11 (9.2%) patients had their exposed bone over mandibular tori (Fig 6). This group accounted for 10 of the 28 (39.3%) cases that developed spontaneous bone exposure and represents an anatomic comorbidity.

### Inciting Event

Knowledge of the inciting or precipitating event can offer an avenue toward prevention. A careful review of the apparent event that resulted in the area of nonhealing exposed bone identified that 30 cases



**FIGURE 7.** A nonhealing extraction socket such as this is a common complication when teeth are removed in patients receiving pamidronate or zoledronate therapy.

Marx et al. *Bisphosphonate-Induced Exposed Bone of Jaws*. *J Oral Maxillofac Surg* 2005.

(25.2%) occurred spontaneously without any apparent dental disease, treatment, or trauma. However, 45 cases (37.8%) were related to the removal of a tooth or teeth (Fig 7), 34 (28.6%) to obvious existing periodontal disease, 5 (11.2%) to periodontal surgery, 4 (3.4%) to a dental implant placement, and 1 (0.8%) to an apicoectomy surgery.

## Mechanism

Although a controlled, randomized, prospective, blinded study to prove the specific causal relationship between bisphosphonate therapy and exposed bone is not possible, the drugs pamidronate, zoledronate, and more rarely alendronate have shown a direct correlation that cannot be ignored. Two theories have been advanced to explain the mechanism for this complication. The leading theory suggests that it is caused by cessation of bone remodeling and bone turnover by the basic osteoclast-inhibiting effect of these drugs, whether given to reduce loss of bone density in osteoporosis or to prevent cancer spread in bone. In osteoporosis treatment, the use of less potent bisphosphonates and the moderately potent bisphosphonates such as alendronate restrict osteoclastic function less severely. The result is usually control rather than cure of osteoporosis, but no significant prevalence of exposed bone is found unless much higher cumulative doses of these bisphosphonates are given over longer durations. This was seen in our 3 cases associated with alendronate, with its half life of more than 10 years. In controlling cancer metastasis, the more potent bisphosphonates pamidronate and zoledronate are known to irreversibly inhibit osteoclasts via interruption of the mevalonate

pathway,<sup>13,14</sup> causing direct toxicity to the osteoclast that results in apoptosis. Thus, osteoclast-mediated resorption by many malignancies through the elaboration of a variety of osteoclast-activating factors such as RANKL is prevented. In the presence of these bisphosphonates, the malignancy cannot resorb a volume of bone into which it can proliferate no matter how many osteoclast-activating factors it secretes. Such is the clinical value of these bisphosphonates, which have dramatically extended life, reduced skeletal complications, reduced pain, and thus improved the quality of life for individuals with metastatic bone cancer.<sup>15,16</sup> Because the jaws have a greater blood supply than other bones and a faster bone turnover rate related both to their daily activity and the presence of teeth (which mandates daily bone remodeling around the periodontal ligament), bisphosphonates are highly concentrated in the jaws. Coupled with chronic invasive dental diseases and treatments and the thin mucosa over bone, this anatomic concentration of bisphosphonates causes this condition to be manifested exclusively in the jaws. Thus, the exposed bone in the jaws is the direct result of the action of these bisphosphonates on the daily remodeling and replenishment of bone. Osteoblasts and osteocytes live for only about 150 days. If, upon their death, the mineral matrix is not resorbed by osteoclasts, which release the cytokines of bone morphogenetic protein and insulin-like growth factors to induce new osteoblasts from the stem cell population, the osteon becomes acellular and necrotic. The small capillaries within the bone become involuted, and the bone becomes avascular. A spontaneous breakdown of the overlying mucosa, some form of injury, or an invasive surgery to the jaws usually causes this necrotic bone to become exposed which then fails to heal.

The competing theory is based only on experimental evidence showing that pamidronate and zoledronate also inhibit capillary neoangiogenesis. Fournier et al<sup>17</sup> have shown that these bisphosphonates inhibit angiogenesis, decrease capillary tube formation, and inhibit vascular endothelial growth factor and vessel sprouting, both in vitro and in a rat model. In addition, Wood et al<sup>18</sup> have shown that bisphosphonates inhibit endothelial proliferation in cultured human umbilical vein and rat aortic ring cells. According to this theory, endothelial cell proliferation may be inhibited in the jaws, leading to loss of blood vessels and avascular necrosis. This theory initially sounds attractive because it would explain why the exposed bone does not bleed upon entry and is obviously avascular. However, more potent antiangiogenic drugs in clinical use today, such as thalidomide,<sup>19</sup> penicillamine/copper depletion,<sup>20</sup> and alpha-2a interferon,<sup>21</sup> as well as those being given in advanced clinical trials, such as endostatin,<sup>22</sup> bortezo-

mide,<sup>23</sup> and angiostatin,<sup>24</sup> have not been shown to produce exposed bone in the jaws.

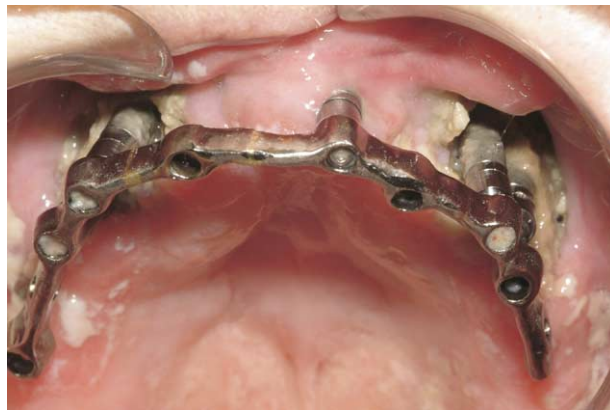Additional support for the anti-osteoclastic mechanism of bisphosphonate-induced exposed bone comes from an understanding of the disease osteopetrosis, an inherited autosomal-dominant trait characterized by the loss of osteoclast development with 7 subtypes. These unfortunate patients develop a clinical picture identical to that of bisphosphonate-induced exposed bone. That is, exposed avascular bone that occurs almost exclusively in the jaws, at times spontaneously but is usually precipitated by an invasive dental procedure and the exposed bone does not resolve. In osteopetrosis as in bisphosphonate-induced exposed bone, angiogenesis in the soft tissues is normal. Further bolstering support for this theory, Whyte et al<sup>25</sup> reported a case of bisphosphonate-induced osteopetrosis in a 12-year-old boy given escalating doses of pamidronate beginning at age 7¾ years. Therefore, the clinician should note that bisphosphonate-induced osteonecrosis is actually a chemically-induced form of osteopetrosis with the clinical course of the disease similar to the genetically related form. The osteonecrosis in each form is the end product of the loss of osteoclastic bone remodeling and renewal.

Obviously, the importance of elucidating the mechanism of this complication is to devise strategies for preventing it. If the underlying mechanism primarily involves bone remodeling, eliminating the diseases and conditions that upregulate bone remodeling before starting bisphosphonate therapy can, in some cases, prevent this complication. Knowledge of the inciting factors offers another means of preventing bone exposure once bisphosphonate therapy has begun.

## Prevention Recommendations

### BEFORE INITIATING BISPHOSPHONATE THERAPY

As soon as the treating oncologist prescribes bisphosphonate therapy, the patient should be referred to an experienced dentist or oral and maxillofacial surgeon for an urgent examination. Close and ongoing communication between the 2 is crucial, and commencement of bisphosphonate therapy should be deferred until dental and oral surgical treatments have been completed. At the minimum, the dental examination should consist of clinical and panoramic radiographic examinations with individual periapical films where indicated. Dental treatment is aimed at eliminating infections and preventing the need for invasive dental procedures in the near and intermediate future. This may include tooth removal, periodontal surgery, root canal treatment, caries control, dental restorations, and dentures. These patients should



**FIGURE 8.** Dental implants in the jaws in patients receiving pamidronate or zoledronate risk implant loss and bone exposure as in this case.

Marx et al. *Bisphosphonate-Induced Exposed Bone of Jaws*. *J Oral Maxillofac Surg* 2005.

not be considered as candidates for dental implants, which have no crevicular epithelial attachment and therefore would predispose the patients in this group to bone exposure (Fig 8). Impacted teeth that are completely covered by bone or soft tissue should be left undisturbed, but those with an oral communication are recommended to be removed and given a 1 month healing period. Similarly, small lingual mandibular tori do not require removal whereas large, multilobed mandibular tori or midline palatal tori with thin overlying mucosa are recommended to be removed 1 month before the initiation of bisphosphonate therapy. Prophylactic antibiotic coverage for noninvasive dental care is not required but is recommended for any invasive dental procedure, and for this penicillin remains the drug of choice. For individuals with a penicillin allergy, combination therapy using quinolones and metronidazole or erythromycin and metronidazole are good second choices and have proven efficacy in this group. Clindamycin alone is not recommended because of its lack of activity against actinomyces, *Eikenella corrodens*, and similar species that have been found to frequently colonize this exposed bone. As a general rule, if the patient requires only noninvasive dental care, such as dental cleanings (prophylaxis), fluoride carriers, dental restorations, dentures, and so forth, bisphosphonate therapy need not be delayed. If the patient requires invasive dental procedures such as tooth removals, periodontal surgery, or root canal therapy, commencement of bisphosphonate therapy should be deferred for 1 month to allow sufficient time for bone recovery and healing. Once the regimen of bisphosphonate therapy has begun, a surveillance schedule of once every 4 months is recommended.

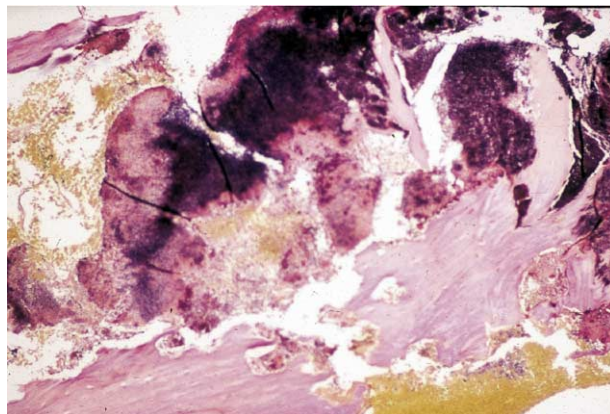
#### WHILE RECEIVING BISPHOSPHONATE THERAPY

Oncologists should consider referring all patients already receiving IV bisphosphonates to a dentist or oral and maxillofacial surgeon for an examination and a surveillance schedule. The dental team should carefully evaluate the oral cavity for exposed bone in the areas most commonly affected, such as the posterior lingual area of the mandible, and for radiographic evidence of osteolysis, osteosclerosis, widened periodontal membrane spaces, and furcation involvements. A dental cleaning and fluoride carriers should be considered, and tooth removal should be avoided if at all possible. If the tooth is nonrestorable because of caries, root canal treatment and amputation of the crown is a better option than removing the tooth. Similarly, teeth that demonstrate 1+ or 2+ mobility should be splinted rather than removed. If the mobility is 3+ or more or is associated with a periodontal abscess, there is a strong possibility that osteonecrosis is already present and the abscess and/or granulation tissue is merely covering exposed bone. In these situations, removing the tooth and providing antibiotic treatment, as described in the previous section, is the only recourse.

Elective surgery within the jaws, such as removal of third molar teeth or tori, periodontal surgery, or placement of dental implants, is strongly discouraged at this time. Denture wearing is acceptable, but the prosthesis should be examined for areas of excessive pressure or friction and given a soft relin if needed.

#### Treatment of Patients With Osteonecrosis of the Jaws

When exposed bone in the jaws is identified by the oncologist or a dentist, the patient should be referred to an oral and maxillofacial surgeon, who can inform the patient of the nature and usual irreversibility of the exposed bone and coordinate treatment with the oncologist. Attempts to accomplish debridements, cover the exposed bone with flaps, or bone-contouring procedures have mostly been counterproductive and have led to further exposed bone, worsening of symptoms, and a greater risk for a pathologic fracture of the jaw. Such procedures are best considered only in cases refractory to nonsurgical management and in the face of continuing symptoms. Even then such procedures carry a risk of further bone exposure, a worsening of symptoms, and deformity (see Fig 3). In bisphosphonate-induced exposed bone, the entire bone is affected and therefore cannot be debrided to a viable bone margin. These procedures have too often resulted in a greater amount of exposed bone. Hyperbaric oxygen, which has proven efficacious in the treatment of osteoradionecrosis by establishing an oxygen gradient, also is of no benefit to the patient



**FIGURE 9.** Colonies of actinomyces are frequently noted on the surface of bisphosphonate induced exposed bone.

Marx et al. *Bisphosphonate-Induced Exposed Bone of Jaws*. *J Oral Maxillofac Surg* 2005.

with bisphosphonate-induced exposed bone. The mechanism of these 2 diseases of bone necrosis is entirely different. Because of the long half life of these bisphosphonates and their great efficacy in stabilizing metastatic cancer deposits in bone, there is no absolute reason to discontinue bisphosphonate therapy. However, if there is no cancer-related indication for continued bisphosphonate therapy or the original indication has resolved, it is reasonable for the oncologist to consider discontinuation of the therapy.

If surgery is mostly counterproductive and hyperbaric oxygen and bisphosphonate discontinuation are of little or no benefit, what can be done for these patients? The answer is that these patients must and can live with some exposed bone. Treatment should be directed at eliminating or controlling pain and preventing progression of the exposed bone. The necrotic exposed bone itself is not painful and will remain structurally sound to support normal jaw function. Once secondarily infected, however, the condition will become painful and may lead to cellulitis and fistula formation, which are more serious. Pathologic fractures do not usually occur unless debridement surgeries have reduced the structural integrity of the mandible. Therefore, aside from rounding off sharp bony projections that produce soft tissue inflammation and pain, debridement surgery is not recommended. Instead, the authors prescribe a long-term (and sometimes permanent) course of penicillin V-K 500 mg 4 times a day and 0.12% chlorohexidine (Peridex; Procter and Gamble), based on the frequent identification of *Actinomyces* species on bone fragments removed from patients with this condition (Fig 9), culture data, and patients' positive clinical response to this regimen.

In refractory or more symptomatic cases, metronidazole (Flagyl; Searle Labs, New York, NY) 500 mg by

mouth 3 times a day is added to this regimen. Occasionally a severe cellulitis will warrant hospital inpatient care using IV antibiotics. In such cases the authors recommend ampicillin 1 g with clavulonate 500 mg (Unaysn 1.5 g; Roerig Division of Pfizer, New York, NY) IV every 6 hours and metronidazole 500 mg IV every 8 hours. In the patient allergic to penicillin, the authors have found it necessary to prescribe a double antibiotic regimen in every case, using either ciprofloxacin 500 mg by mouth twice a day or erythromycin ethylsuccinate 400 mg by mouth 3 times a day combined with metronidazole 500 mg by mouth 3 times a day.

### Outcomes of Management

Of the 97 patients treated with this antibiotic regimen and followed for 1 year or longer, 6 died of the cancer underlying their condition. Three of the remaining 91 patients (3.3%) required a short hospitalization for a cellulitis and pain that were controlled with IV antibiotics and wound irrigation. Nine patients (9.9%) experienced intermittent episodes of pain that required an adjustment of or addition to their antibiotic regimen and chairside daily wound irrigations with half-strength hydrogen peroxide or 0.12% chlorohexidine Peridex (Proctor and Gamble). The remaining 82 patients (90.1%) functioned free of pain without a change in antibiotic coverage or the need for chairside wound irrigations. None of the patients developed a jaw fracture. The 2 patients who had an exposed titanium plate from a previous surgery and the 11 patients who had an orocutaneous fistula remained unchanged, although drainage of the fistula had either ceased altogether or was significantly reduced in each of the latter patients.

The authors hope this article will increase the awareness of bisphosphonate-induced bone among oncologists, oral and maxillofacial surgeons, and dentists, all of whom are in a position to suspect or make an initial discovery of this complication of cancer therapy. The data presented here are intended to guide each of these groups in taking appropriate measures to recognize the risk factors associated with this complication and the risks of exposed bone itself as well as some reasonable means of preventing and treating it. The authors believe the benefits of IV bisphosphonate therapy far outweigh the risk of developing bisphosphonate-induced exposed bone, which remains very low among the 250,000+ patients who receive these medications worldwide. Moreover, the success that has been documented in containing or controlling osteonecrosis of the jaws following the guidelines described in this article further supports the continued use of these IV bisphosphonates where indicated.

There are several lessons to be learned by our experience with this complication. First, despite over 8 years of preclinical and clinical trials with long-term follow-up, this complication remained unrecognized, a fact that should serve to remind us that animal physiology, particularly animal bone physiology, is much more forgiving to insult than human bone physiology. Second, it shows that systemic drug-related complications may take years to be recognized clinically and even then may be misinterpreted as another disease or etiology. In this complication, early cases were thought to represent mere jaw infections (osteomyelitis) related to the immunosuppressive effects of chemotherapy. In fact, in the same issue of the journal that published the first reported cases linking this type of exposed bone to bisphosphonates, an article by Wang et al<sup>26</sup> reported 3 cases attributed to the late effects of chemotherapy, and yet all 3 were reported to have been taking pamidronate. Finally, the reader should be as concerned as the authors about the small number (3) of osteonecrosis of the jaws cases related to alendronate in the present series, in the series published by Ruggerio et al<sup>3</sup> (7 cases), and in the report published by Carter and Gross (1 case).<sup>4</sup> The trends in our patient data show that risks for bisphosphonate-induced exposed bone are related to the stereochemistry of the nitrogen side chain, the cumulative bisphosphonate dose, the duration of therapy, the presence of medical and dental comorbidities, the presence of pre-existing dental disease, and invasive dental procedures. Given that it has a half-life of more than 10 years, the current widespread use of alendronate to prevent or treat early osteoporosis in relatively young women and the likelihood of long-term use as well as the ubiquitous presence of dental disease in our society give us cause for concern.

### References

1. Marx RE: Pamidronate (Aredia) and zoledronate (Zometa) induced avascular necrosis of the jaws: A growing epidemic. *J Oral Maxillofac Surg* 61:1115, 2003
2. Migliorati CA: Bisphosphonates and oral cavity avascular bone necrosis. *J Clin Oncol* 21:4253, 2003
3. Ruggerio SI, Mekrotra B, Engroff SL: Osteonecrosis of the jaws associated with the use of bisphosphonates. A review of 63 cases. *J Oral Maxillofac Surg* 62:527, 2004
4. Carter GD, Gross AN: Bisphosphonates and avascular necrosis of the jaw. *Aust Dent J* 48:268, 2003
5. Estilo CL, Van Poznak CH, Williams T, et al: Osteonecrosis of the maxilla and mandible in patients treated with bisphosphonates: A retrospective study. *Proc Am Soc Clin Oncol* 22:750, 2004 (abstr)
6. Martin TJ, Gill V: Bisphosphonates—Mechanism of action. Experimental and clinical pharmacology. *Auctr Preser* 23:130, 2000
7. Marx RE: Osteoradionecrosis—A new concept of its pathophysiology. *J Oral Maxillofac Surg* 41:351, 1983

8. Marx RE, Johnson RP: Studies in the radiobiology of osteonecrosis and their clinical significance. *Oral Surg Oral Med Oral Pathol* 64:379, 1987
9. Zigic TM, Marcous C, Hungerford DS, et al: Corticosteroid therapy associated with ischemic necrosis of bone in systemic lupus erythematosus. *Am J Med* 79:596, 1985
10. Miller KD, Masur H, Jones EC, et al: High prevalence of osteonecrosis of the femoral head in HIV-infected adults. *Ann Intern Med* 137:17, 2002
11. Abu-Shakra M, Buskila D, Shoenfeld Y: Osteonecrosis in patients with SLE. *Clin Rev Allergy Immunol* 25:13, 2003
12. Ghreck CJ, Freilberg R, Gruppo R, et al: Thrombophillia and hypofibrinolysis, in Urbaniak RJ, Jones JP (eds): *Reversible Pathogenetic Etiologies of Osteonecrosis in Osteonecrosis: Etiology, Diagnosis and Treatment*. Rosemont, IL, American Academy of Orthopedic Surgeons, 2001, pp 105-110
13. Beek ER, Lowick CWGM, Papapoulos SE: Bisphosphonates suppress bone resorption by a direct effect on early osteoclast precursors without affecting the osteoclastogenic capacity of osteogenic cells: The role of protein geranylgeranylation in the action of nitrogen-containing bisphosphonates or osteoclast precursors. *Bone* 30:64, 2002
14. Rogers MJ, Gordon S, Benford HL, et al: Cellular and molecular mechanisms of action of bisphosphonates: Skeletal complications of malignancy. *Cancer Suppl* 88:2961, 2000
15. Hortobagyi GN, Theriault RL, Porter L, et al: Efficacy of pamidronate in reducing skeletal complications in patients with breast cancer and lytic bone metastases. *N Engl J Med* 335:1785, 1996
16. Beresen JR, Lichtenstein A, Porter L, et al: Efficacy of pamidronate in reducing skeletal events in patients with advanced multiple myeloma. *N Engl J Med* 334:488, 1996
17. Fournier P, Boissier S, Filleur S, et al: Bisphosphonates inhibit angiogenesis in vitro and testosterone-stimulated vascular re-growth in the ventral prostate in castrated rats. *Cancer Res* 62:6538, 2002
18. Wood J, Bongean K, Ruetz S, et al: Novel antiangiogenic effects of the bisphosphonate compound zoledronic acid. *J Pharm Exp Theropuctus* 302:1055, 2002
19. D'Amato RJ, Loughman MS, Flynn E, et al: Thalidomide is an inhibitor of angiogenesis. *Natl Acad Sci U S A* 91:4082, 1994
20. Brem S, Zagzag D, Tsanaclis AM, et al: Inhibition of angiogenesis and tumor growth in the brain. Suppression of endothelial cell turnovers by penicillamine and the depletion of copper, an angiogenic cofactor. *Am J Pathol* 134:1121, 1990
21. Kaban LB, Mullchen, JB, Ezekowitz RA, et al: Antiangiogenic therapy of a recurrent giant cell tumor of the mandible with interferon alfa-2a. *Pediatrics* 103:1145, 1999
22. O'Reilly MS, Boehn T, Skmy J, et al: Endostatin, an endogenous inhibitor of angiogenesis and tumor growth. *Cell* 88:277, 1997
23. Stinchcombe TE, Mitchell BS, Depcets-Smith N, et al: PS-341 (Bortazomib) is active in multiple myeloma. Preliminary report of a phase I trial of the proteasome inhibitor PS-341 in patients with hematologic malignancies. *Blood* 96:516a, 2000 (abstr)
24. Sim BK, O'Reilly MS, Liang H, et al: A recombinant human angiostatin protein inhibits experimental primary and metastatic cancer. *Cancer Res* 57:1329, 1997
25. Whyte M, Venhert D, Clements KL, et al: Bisphosphonate-induced osteopetrosis. *N Engl J Med* 349:457, 2003
26. Wang J, Goodgen NM, Pogrel MA: Osteonecrosis of the jaw associated with cancer chemotherapy. *J Oral Maxillofac Surg* 62:91, 2004